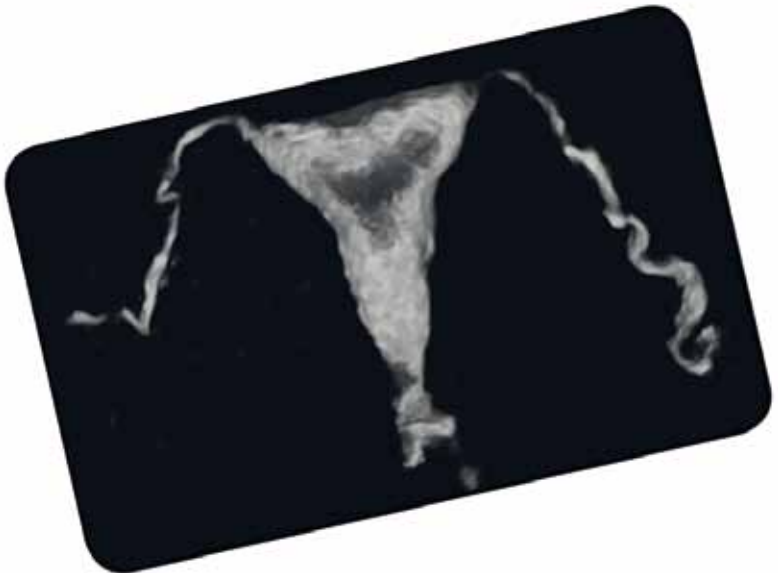


GE Healthcare

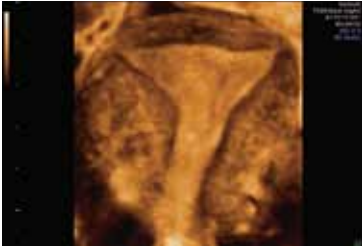# Ultrasound procedure in Infertility

Dr Martin Hynek and Dagmar Smetanova

Gennet, Centre for genetics and reproductive medicine  
Prague, Czech Republic

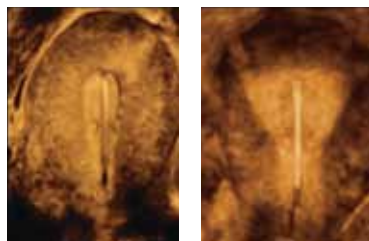
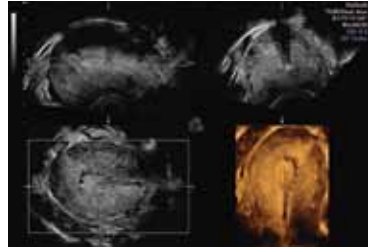


## 1. Normal Uterus C plane

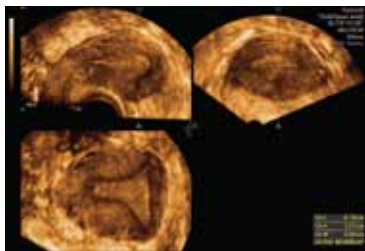


3D surface rendered ultrasound images showing normal uterus. The initial plane for obtaining the 3D volume is a strict mid-sagittal view of the uterus, and 3D volume is acquired using a sweep angle of 90-120°, to ensure the whole uterus is included. The rendering box is then placed over the endometrium and a part of myometrium, and the green line is curved to follow the course of the endometrium if necessary. With this technique it is possible to obtain a coronal view of the uterus which is usually perpendicular to the ultrasound beam and not obtainable using 2D ultrasound. The unique advantage of the coronal plane is that we are easily able to assess both the shape of the uterine cavity and the uterine fundus in one image. The pictures show the normal uterus, in which fundal contour is straight or convex (no fundal indentation) and external uterine contour convex or with slight indentation < 10 mm.

## 2. IUD Uterus C plane

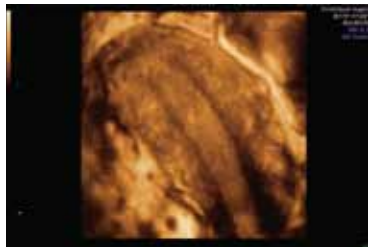


3D surface rendered ultrasound images showing a position of the intrauterine device (IUD) in the normal uterus. The rendering box is placed over the endometrium with the IUD and the coronal plane is reconstructed. 3D view enables us to assess the correct position of the IUD inside the uterine cavity, regarding both the distance from the fundus as well as the deviation from the midline.



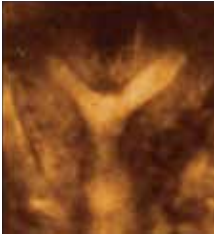3D ultrasound image of the normal uterus. The initial plane for obtaining the 3D volume is a strict mid-sagittal view of the uterus (Window A). Window B shows the axial plane and Window C the coronal plane. Exact measurements of uterine length, width and thickness are easily feasible, giving us a complex view of the uterine size. The uterine volume can be estimated.

## 3. Uterus anomalies C plane



3D surface rendered ultrasound image of the unicornuate uterus (Type II using the American Fertility Society (AFS) classification<sup>(1)</sup>). In cases of uterine malformations the volume may also be obtained from the transverse plane allowing sometimes even better estimation of the cavity/fundus relationship in the 3D reconstruction. The arrest of development of one Müllerian duct resulting in the presence of only one half of the uterus with only one horn is clearly apparent.

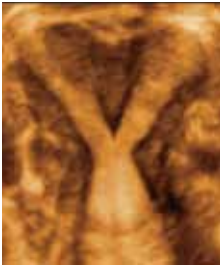#### 4. Uterus anomalies C plane



3D surface rendered ultrasound image of partial bicornuate uterus (AFS Type IVb). We can spot two well-formed uterine cornua. To distinguish bicornuate uteri from septate uteri: a line adjoining both uterine horns is drawn. If this line

crossed the fundus or is  $\leq 5$  mm from it, the uterus is considered bicornuate; if it is  $\geq 5$  mm from the fundus, the uterus is regarded as septate<sup>(2)</sup>.

#### 5. Uterus anomalies C plane



3D surface rendered ultrasound image of complete bicornuate uterus (AFS Type IVa). As on previous image we observe two well-formed uterine cornua and the line joining both horns crosses the fundus. Unicornuate or bicornuate uteri represent the unification defects of the

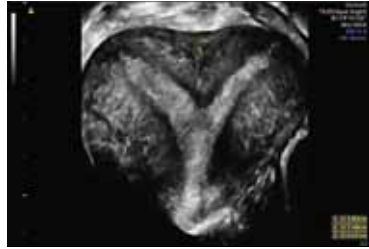
Müllerian ducts and are associated with increased rates of mis-carriage, preterm delivery and fetal malpresentation<sup>(3)</sup>.

#### 6. Uterus anomalies C plane



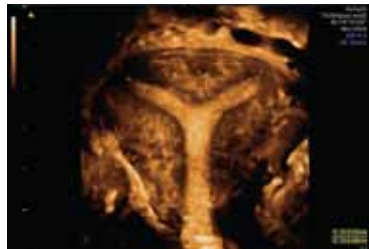
3D surface rendered ultrasound image of complete septate uterus (AFS Type Va). The septum between two uterine horns in this complete form extends to the internal cervical os. The external uterine contour is typically convex or slightly concave (with indentation  $< 10$  mm). Differentiation between a septate and a bicornuate uterus is of a crucial importance as septate uterus is treated using hysteroscopic resection of the septum, whereas a bicornuate one requires more complex abdominal metroplasty.

#### 7. Uterus anomalies C plane



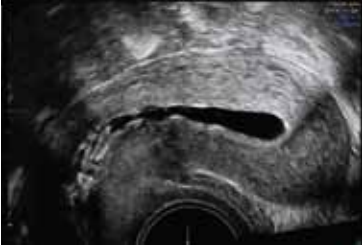3D surface rendered ultrasound image of partial septate (subseptate) uterus (AFS Type Vb). The septum between two uterine horns does not reach the internal cervical os. The external uterine contour is slightly concave (with indentation  $< 10$  mm) and apparently, the line joining both horns is  $> 5$  mm from the fundus, which differentiates the septate uterus from the bicornuate one. As for the differentiation from the arcuate uterus we assess the fundal contour: the fundal indentation in a partial septate uterus appears as an acute angle at the central point<sup>(4)</sup> or  $> 1.5$  cm deep<sup>(5)</sup>, whereas arcuate uterus has the fundal indentation with an obtuse angle at the central point or  $< 1.5$  cm deep. Septate and subseptate uteri belong to the canalization defects of the Müllerian ducts; they reduce the chance of clinical pregnancy and increase the rate of miscarriage, preterm delivery and fetal malpresentation<sup>(3)</sup>.

#### 8. Uterus anomalies C plane



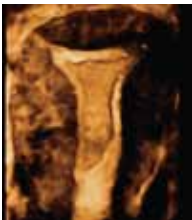3D surface rendered ultrasound image of arcuate uterus (AFS Type VI). As can be seen the fundal indentation in arcuate uterus appears with an obtuse angle at the central point and  $< 1.5$  cm deep. The findings of arcuate uteri appear to be specifically associated with increased risk of second-trimester miscarriage<sup>(4)</sup>.

## 9. 2D sagittal plan hysterosonography



Hysterosonography represents an ultrasonic non-invasive procedure in which uterine cavity is instilled with sterile saline. The expanded cavity is subsequently explored using 2D and 3D ultrasound and saline works as a negative contrast media markedly enhancing the presence of uterine malformations, polyps or fibroids. The image shows 2D sagittal view of the uterus. The thin catheter is placed into the uterine cervix (see the image) and while ultrasound scan is performed, 3-5 ml of sterile saline is slowly instilled which gradually dilates the endometrial cavity. Both anterior and posterior portions of endometrium are widely separated helps detect pathology.

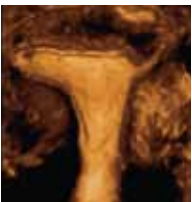## 10. 3D sagittal plan hysterosonography 1



3D surface rendered image of hysterosonography of normal uterine cavity. After the saline is instilled into uterine cavity, the longitudinal view of the uterus is obtained and 3D volume with a sweep angle 120° is acquired. The render box is placed over the

cavity with the green line looking on the anterior or posterior uterine wall as desired, curving the line to trace the shape of the cavity, helping to examine its shape.

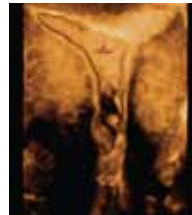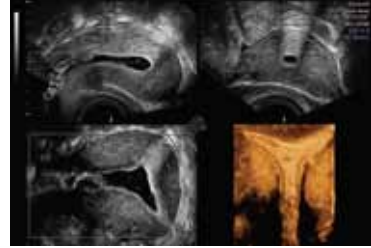
## 11. 3D sagittal plan hysterosonography 2



3D surface rendered hysterosonographic image showing normal uterus. As can be seen, the uterine cavity is of a normal shape, spacious, both horns are symmetrical, normal fundal contour with no indentation and normal

external contour. The endometrial surface is smooth and regular with no protruding fibroids or polyps. Studies indicate that contrast media such as saline can increase the specificity of sonography in diagnosing a variety of intrauterine lesions<sup>6,7</sup>.

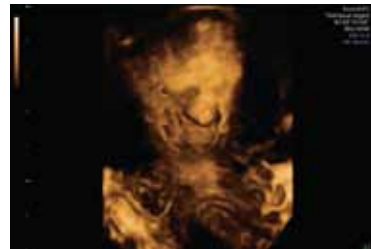## 12. 3D rendering HSG with myoma 1



3D surface rendered images from hysterosonography showing submucous myoma. After the uterus is instilled with saline, there is an apparent submucous myoma low in the cavity protruding from the right posterior wall. The method

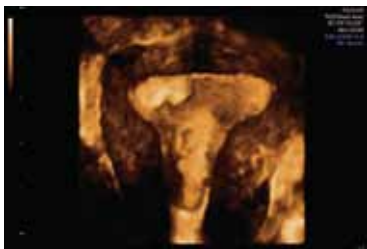helps in differentiating the correct localization of myomas as for being intramural versus submucous<sup>7</sup> which is of a great importance when deciding the optimal clinical management.

## 13. 3D rendering HSG with polypes



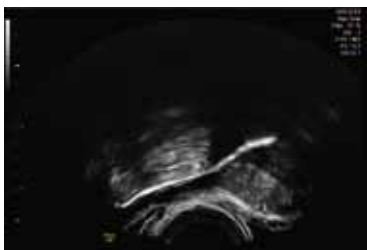
These hysterosonographic 3D surface rendered images present lateral and coronal views on uterine cavity. Apparently, a considerable proportion of the cavity is obliterated with multiple polypoid structures, originating from fundus, posterior wall and left uterine horn.

## 14. 3D rendering HSG with polyps



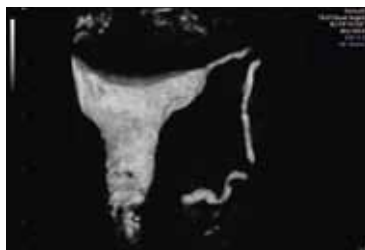Finally, 3D reconstruction of the uterus after saline hysterosonography shows two endometrial polyps near right uterine corner. Interestingly, in this case there were no signs of endometrial pathology on conventional 2D sonogram.

## 15. 2D tube picture with ExEm foam



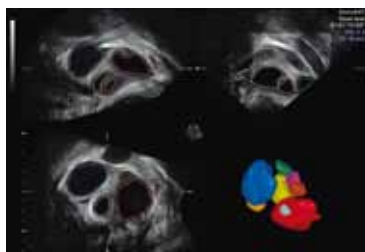
Tubal patency is one of the clue issues when dealing with infertility problems. Hysterosono-salpingography with ExEm® foam represents an easy and non-invasive ultrasonic methods how to assess the Fallopian tubes and verify the tubal patency. The foam is prepared by vigorous mixing of ExEm® gel with purified water creating foam that works as a very strong positive contrast (little air bubbles are highly echogenic) and has a low viscosity to be able to pass sufficiently through patent tubes. The procedure starts with the placement of the catheter into the cervix, in a minority of cases with a help of tenaculum. Afterwards the ultrasound transducer is introduced into the vagina and uterus visualized in the longitudinal plane. As the foam is highly echogenic, the power should be reduced to 60 % and the gain lowered to obtain a good contrast between the foam and adjacent structures. Subsequently, the foam is administered via the catheter into the uterine cavity. After identifying the foam inside the cavity, we tilt and rotate the transducer to one and the other sides of the uterus to visualize the passage of the foam through Fallopian tubes. As can be seen on 2D image the foam depicts the tube as a distinct white echogenic line.

## 16. 3D rendering picture with ExEm foam



After administration of the ExEm® foam during hysterosono-salpingography the 3D volume can be acquired and 3D surface rendering reconstruction of the uterus and tube performed. The volume is started from the longitudinal view of the uterus using wide 120° sweep. The render box is placed over the uterus and the assumed course of the tube. After decreasing the gain the 3D reconstruction of the uterus and tube will appear. Finally, using MagiCut feature we can erase all unnecessary structures apart from the uterus and the tube. The final result can be appreciated on the image showing the true cast of uterine cavity and the complete course of the tube.

## 17. 2D ovary stimulation9. day of stimulation



2D- and 3D images show the stimulated ovary on the 9<sup>th</sup> day of the stimulation. Using 3D ultrasound facilitates standard measurement of follicular diameter due to the fact that during last stage of stimulation the ovaries may contain many large follicles which cause the measurement harder and less reliable using 2D ultrasound<sup>(6)</sup>. SonoAVC™ makes the measurements even easier as it depicts and measures follicles semi-automatically and facilitates the monitoring of the follicular growth.

© 2012 General Electric Company – All rights reserved.  
GE Healthcare, a division of General Electric Company.

General Electric Company reserves the right to make changes in specifications and features shown herein, or discontinue the product described at any time without notice or obligation. Contact your GE representative for the most current information.

General Electric Company, doing business as GE Healthcare.

GE and GE Monogram are trademarks of General Electric Company.

DOC1180825

**EUROPE**  
GEHealthcare GmbH  
Beethovenstr. 239  
D-42655 Solingen  
T 49 212-28 02-0  
F 49 212-28 02 28

**UNITED KINGDOM**  
GE Medical Systems Ultrasound  
2, Napier Road  
Bedford MK41 0JW  
Phone: (+44) 1234 340881  
Fax: (+44) 1234 266261

**AMERICAS**  
GE Medical Systems  
Milwaukee, WI, USA  
Fax: (+1) 262 544-3384

**ASIA**  
GE Medical Systems  
Tokyo, Japan  
Fax: (+81) 3-3223-8524  
Shanghai, China  
Fax: (+86) 21-5208 0582

Visit us online at:  
[www.gehealthcare.com](http://www.gehealthcare.com)

## Reference

1. AFS. The American Fertility Society classifications of adnexal adhesions, distal tubal occlusion, tubal occlusion secondary to tubal ligation, tubal pregnancies, mullerian anomalies and intrauterine adhesions. *Fertil Steril* 1988; 49: 944-955.
2. Troiano R, McCarthy S. Müllerian duct anomalies: imaging and clinical issues. *Radiology* 2004; 233: 19-34.
3. Chan YY, Jayaprakasan K, Tan A, Thornton JG, Coomarasamy A, Raine-Fenning NJ. Reproductive outcome in women with congenital uterine anomalies: a systematic review. *Ultrasound Obstet Gynecol* 2011; 38: 371-382.
4. Woelfer B, Salim R, Banerjee S, Elson J, Regan L, Jurkovic D. Reproductive outcomes in women with congenital uterine anomalies detected by three-dimensional ultrasound screening. *Obstet Gynecol* 2001; 98: 1099-1103.
5. Syed I, Hussain H, Weadock W, Ellis J. Imaging in Mullerian duct abnormalities *eMedicine*. <http://emedicine.medscape.com/article/405335-overview> [Accessed 10 February 2012].
6. La Torre R, De Felice C, De Angelis C, Coacci F, Mastrone M, Cosmi EV. Transvaginal sonographic evaluation of endometrial polyps: a comparison with two dimensional and three dimensional contrast sonography. *Clin Exp Obstet Gynecol* 1999; 26: 171-173.
7. Sylvestre C, Child TJ, Tulandi T, Tan SL. A prospective study to evaluate the efficacy of two- and three-dimensional sonohysterography in women with intrauterine lesions. *Fertil Steril* 2003; 79: 1222-1225.
8. Raine-Fenning N, Fleischer AC. Clarifying the role of three-dimensional transvaginal sonography in reproductive medicine: an evidence-based appraisal. *J Exp Clin Assis Reprod* 2005; 2: 10.



GE imagination at work