

3D fibroid classification



Bernard Benoit

Centre Hospitalier Princesse
Grace, Monaco

Jean Marc Levailant

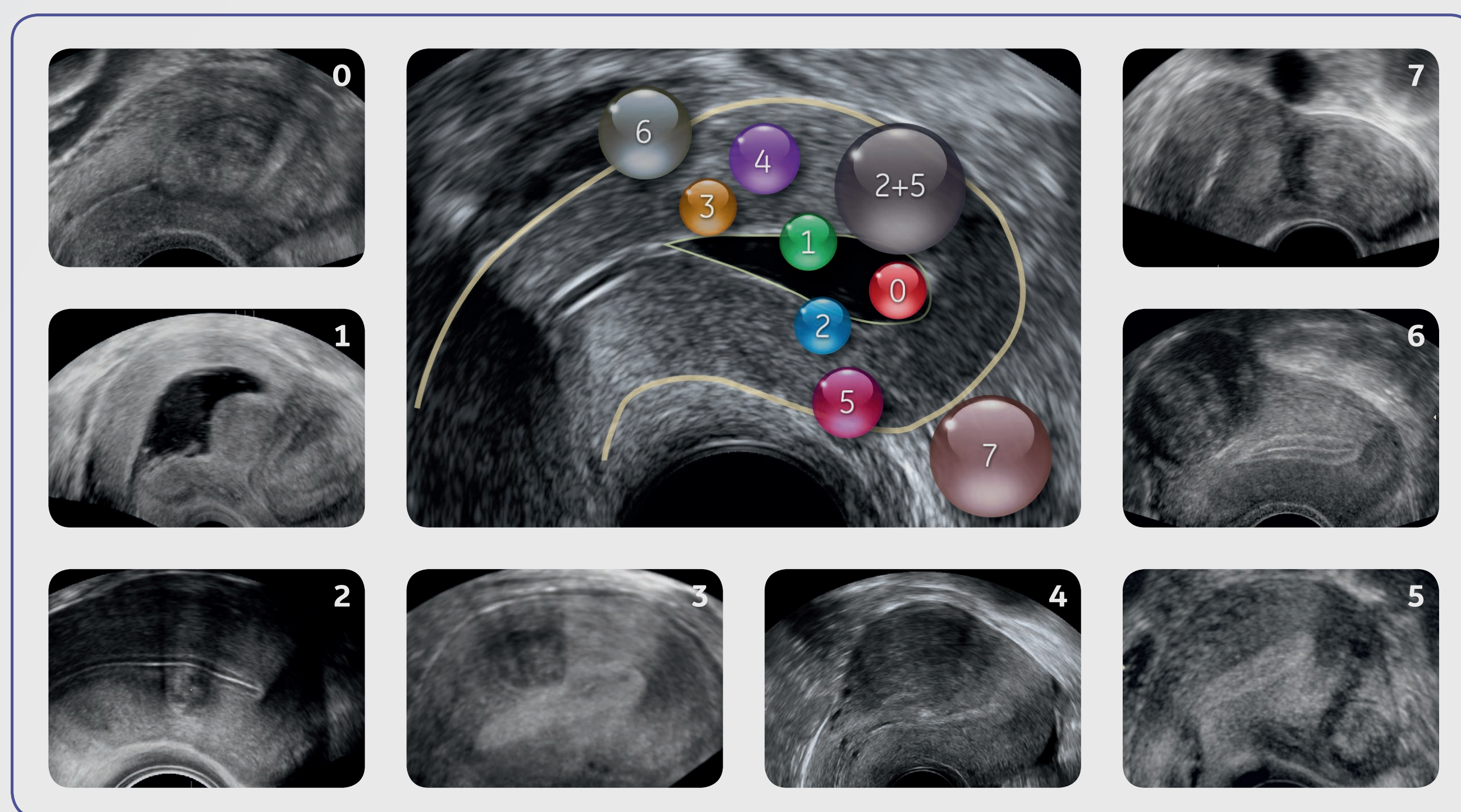
Kremlin Bicêtre Hospital,
France

Guillaume Legendre

Kremlin Bicêtre Hospital,
France

Hervé Fernandez

Kremlin Bicêtre Hospital,
France

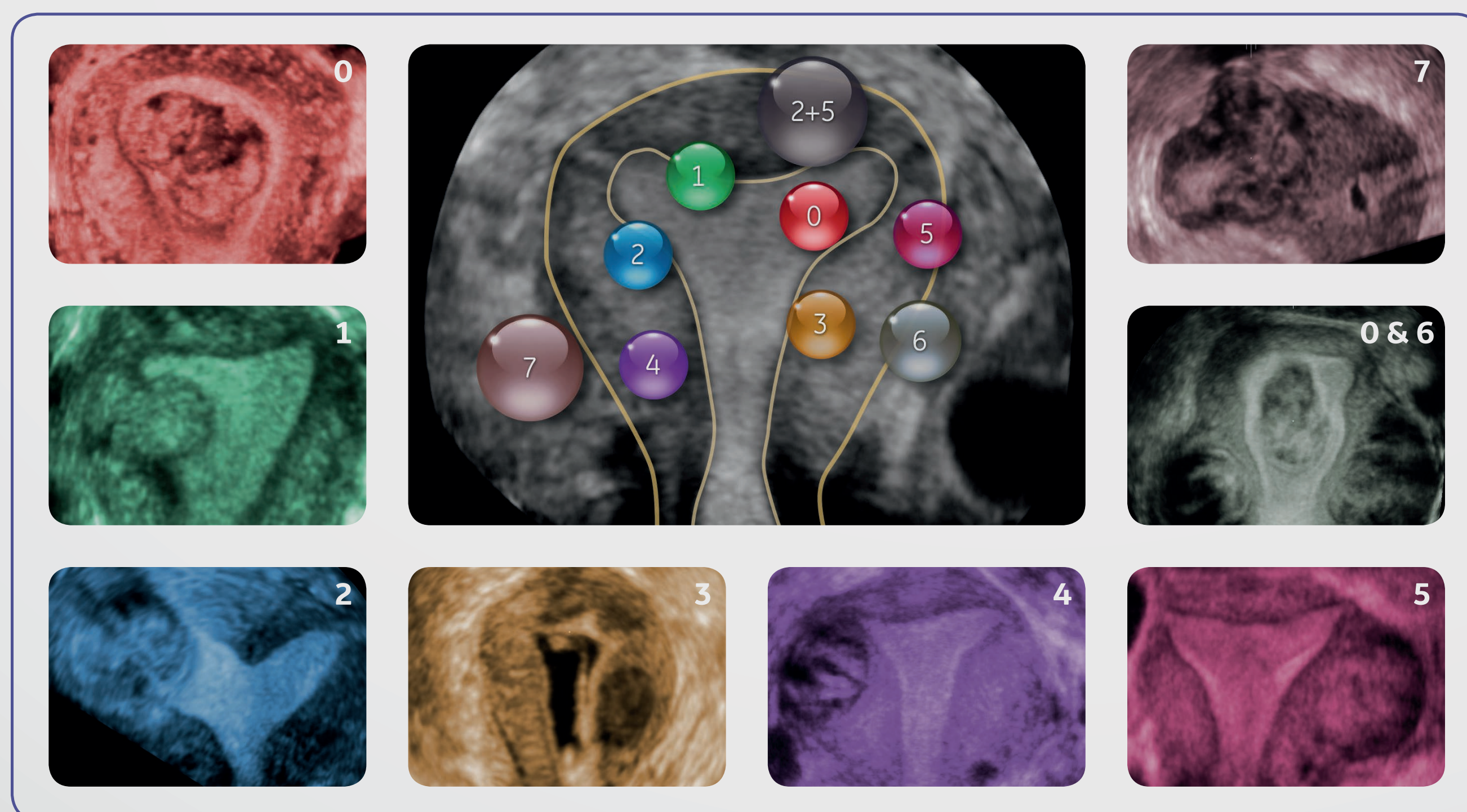


Submucosal

- 0 Pedunculated intracavitary
- 1 <50% intra mural
- 2 ≥50% intra mural

Other

- 3 Contact endometrium, 100% intra mural
- 4 Intra mural
- 5 Subserosal ≥50% intra mural
- 6 Subserosal <50% intra mural
- 7 Subserosal pedunculated
- 8 Other (specify e.g. cervical, parasitic)



Hybrid

- 2-5 Submucosal and subserosal, each with less than half the diameter in the endometrial and peritoneal cavities, respectively